



High Precision Radiation Therapy for Cancers of the Upper Abdomen

Laura A. Dawson, M.D.

Princess Margaret Hospital, University of Toronto,
Toronto, Ontario, Canada



Princess Margaret Hospital
University Health Network

Disclosures

Funding from

Elekta Oncology

Bayer

Outline: RT for Upper Abdominal Ca

Historical (dismal) role of RT

Overcoming challenges

Example – RT for hepatocellular carcinoma

Future (promising) role of RT

Historical (Dismal) Role of RT – Why?

- Challenging to select appropriate patients
 - Local, regional and distant occult metastases
- Tumorcidal dose RT not possible to deliver
 - Tumor delineation
 - Moving organs
 - Many critical normal tissues
- Normal tissue toxicity
 - Parallel fn organs – liver, kidneys
 - Serial fn organs - stomach, small bowel, spinal cord...
 - Low whole organ RT tolerances
 - Partial organ tolerances not established

Potential Toxicities

- Hepatic injury
 - Radiation induced liver disease (RILD)
 - Anicteric ascites, hepatosplenomegaly
 - Elevated liver enzymes (ALP > AST/ALT)
 - Non-RILD hepatic toxicity
 - Elevation of transaminases
 - Reactivation of viral hepatitis
 - Liver decompensation
- Biliary stricture
- Renal failure
- Stomach, duodenal, colon bleeding, obstruction, fistula, ...

How to Deliver RT Safely

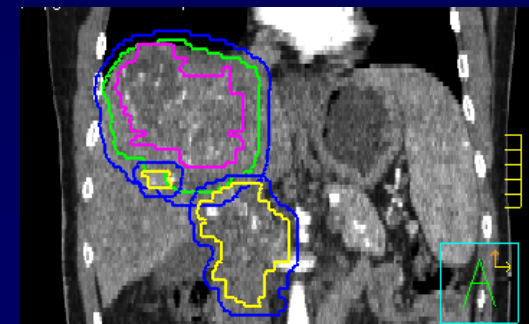
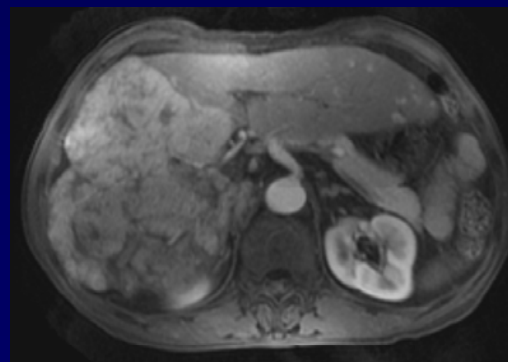
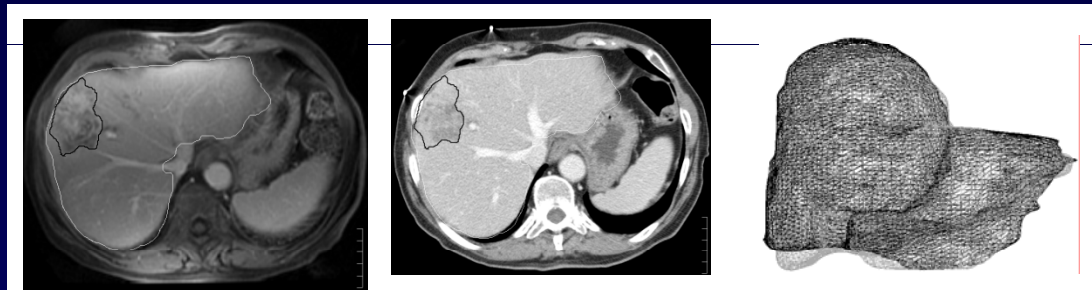
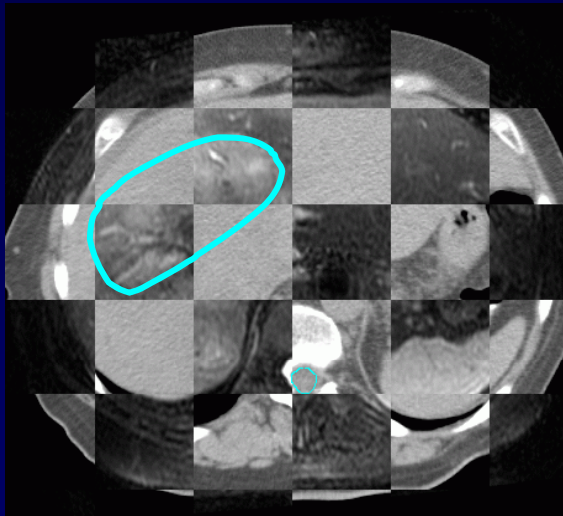
- Requires RT technological advances
 - Imaging
 - Breathing motion management
 - Planning
 - Image guidance
- Understand normal tissues tolerances
- Appropriate patient selection
- Improve integration of RT with other therapies

Technological Advances

- Improved imaging
 - Tumor definition
 - Image fusion (CT, MRI)
 - Respiratory sorting
 - Motion measurement
- Conformal, computer aided RT planning
- Breathing motion management
- Image guided radiotherapy (IGRT)

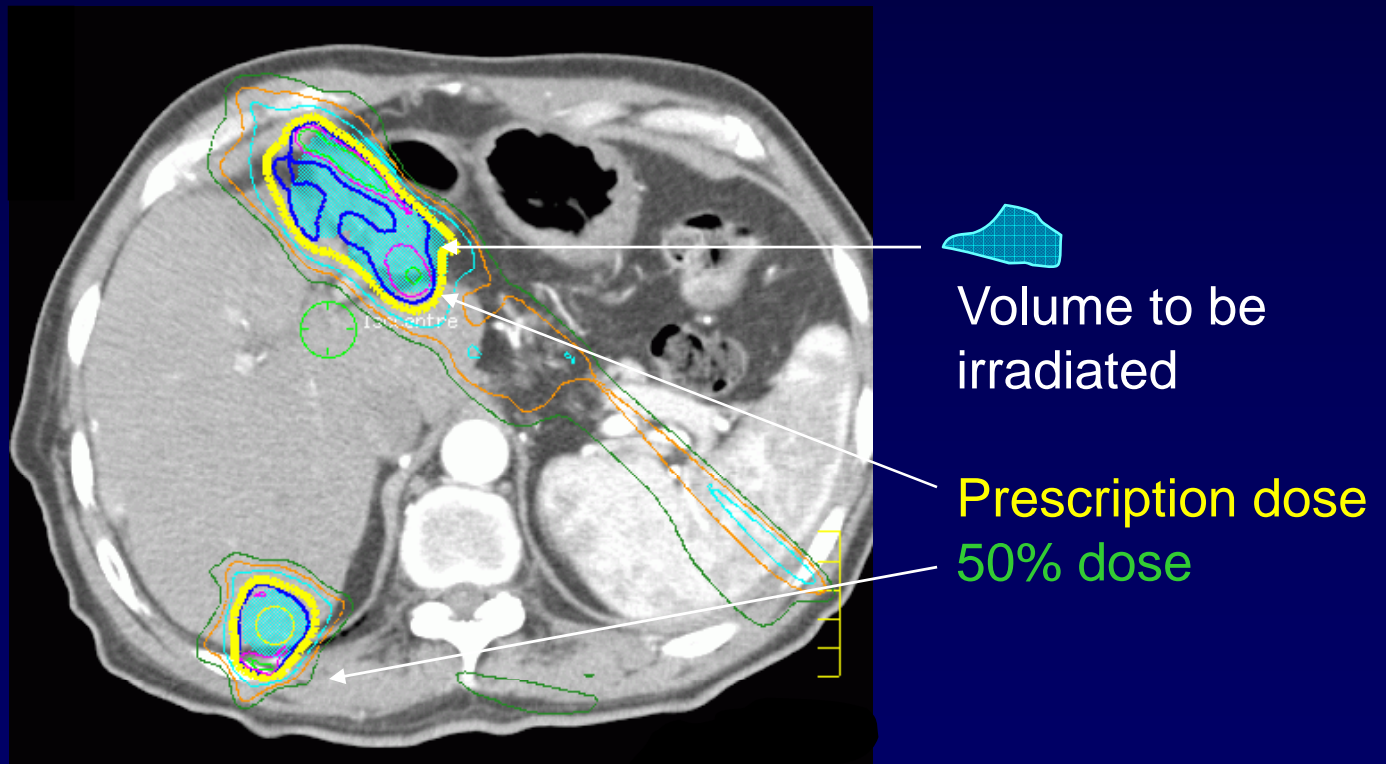
Imaging

- Multi-modal imaging: CT, MR, PET
- Multi-phasic imaging: CT, MR
 - Arterial - HCC, Venous - portal vein thrombus
- Image registration and fusion



Radiation Planning

- Geometric conformation of dose
- Intensity modulated radiation therapy
- Automated computer optimization



Breathing Motion Management

- Breathing motion measurement (1 – 3 cm)
 - Fluoroscopy, cine MR, respiratory sorted CT
- Motion management strategies
 - Increase volume irradiated
 - Breath hold
 - Gating beam
 - Track beam

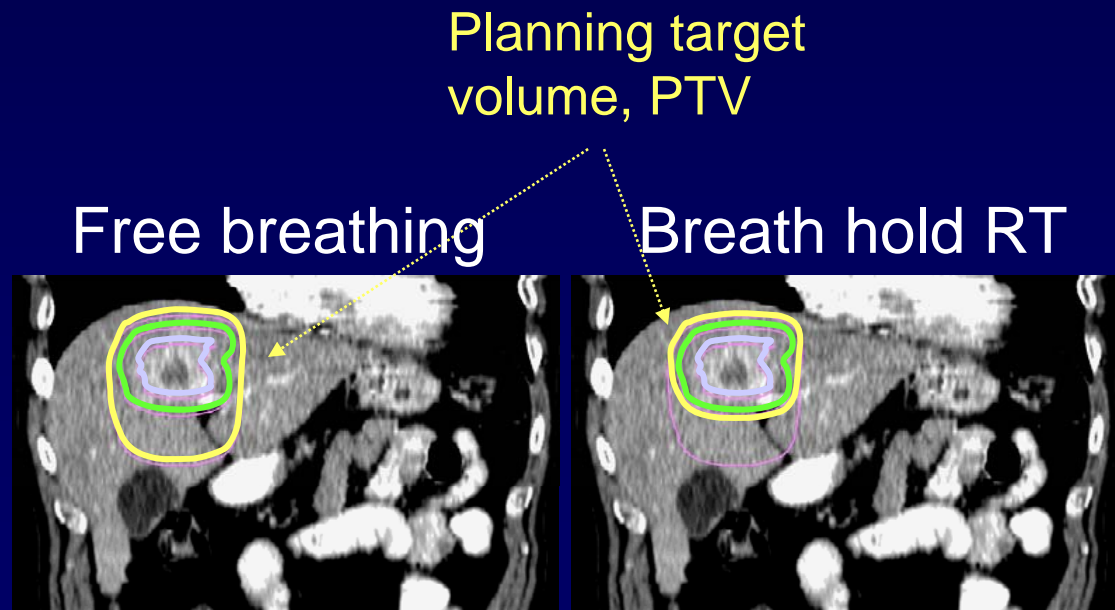
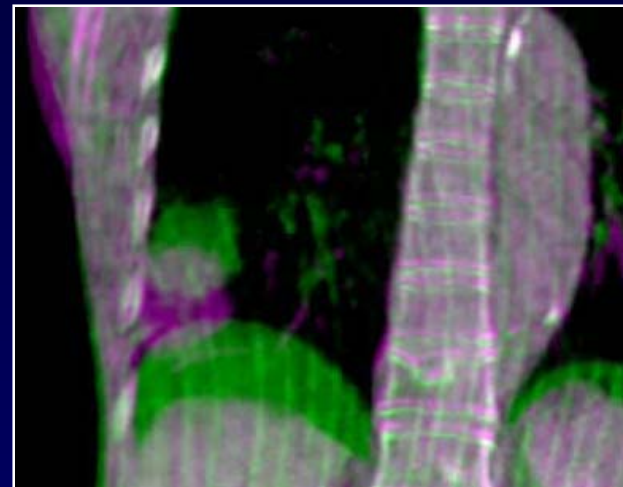
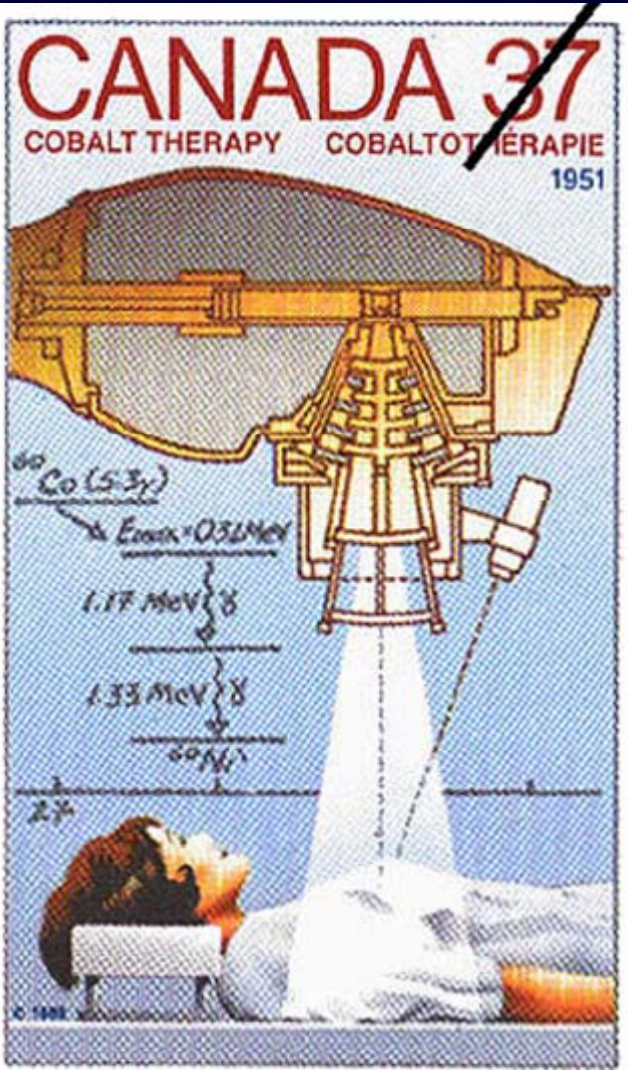


Image Guided Radiation Therapy, IGRT

- IGRT = Daily imaging immediately before or during RT delivery to position patient more accurately and precisely
- Changes in upper abdo organ position day-to-day ---->
 - Free breathing
 - Breath hold
- IGRT increases likelihood of dose being delivered as planned
 - Improved tumor control & less toxicity



IGRT Is Not New



1951 Johns & Cunningham, Canada
Co60 & xray designed

1958 Co60-xray implemented

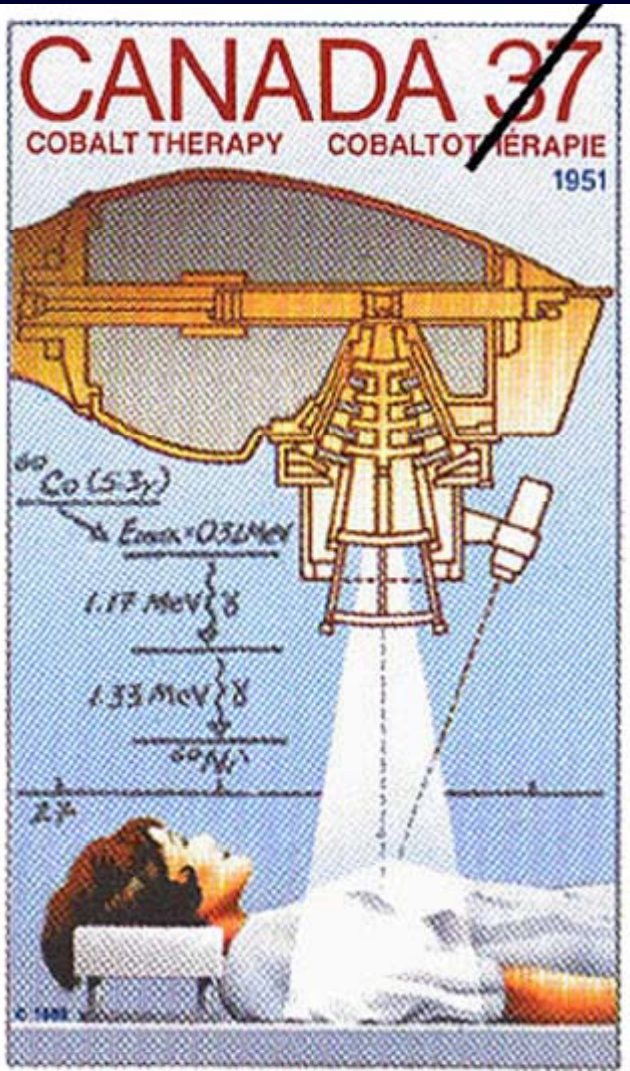
1958 Lokkerbol, Netherlands

Linac & retractable xray tube designed

1961 Linac-xray implemented

Canadian stamp demonstrating
image guided Cobalt from 1951

IGRT Is Not New



Canadian stamp demonstrating image guided Cobalt from 1951

1951 Johns & Cunningham, Canada
Co60 & xray designed

1958 Co60-xray implemented

1958 Lokkerbol, Netherlands

Linac & retractable xray tube designed

1961 Linac-xray implemented

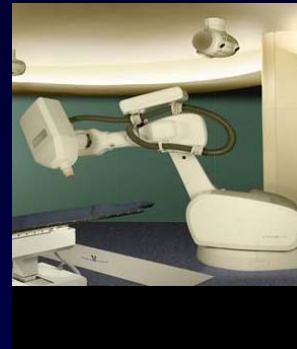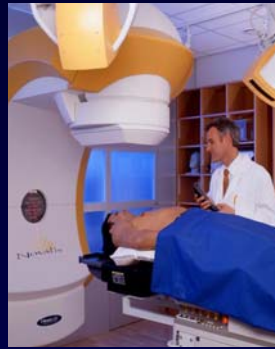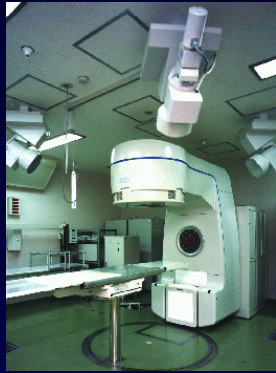Why didn't IGRT catch on previously?

- Not efficient
- Less rationale, since other challenges limited RT doses

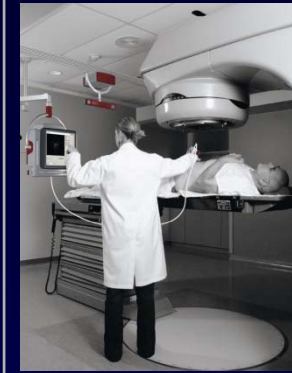
IGRT 2008



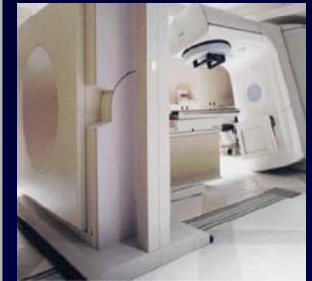MV EPID



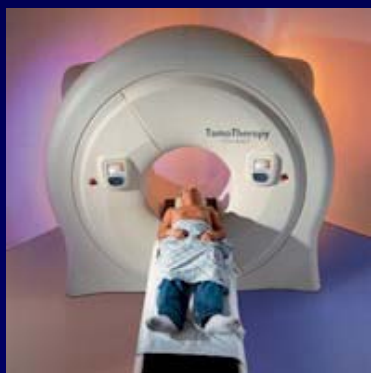kV Fluoroscscopy + markers



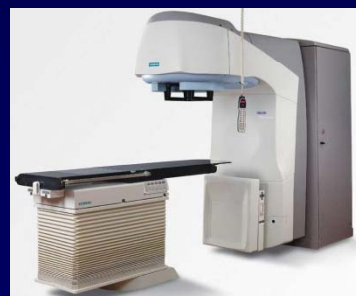Ultrasound



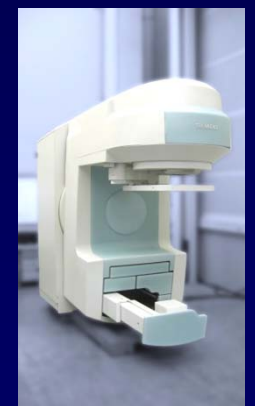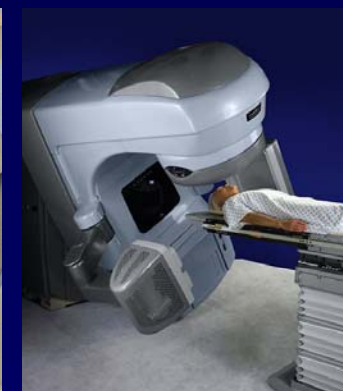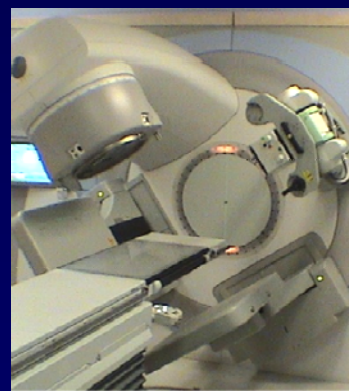kV CT



MV CT



MV cone
beam CT

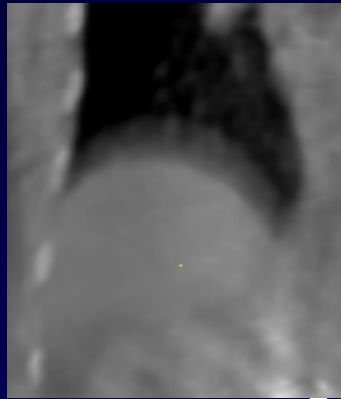


kV Cone-beam CT

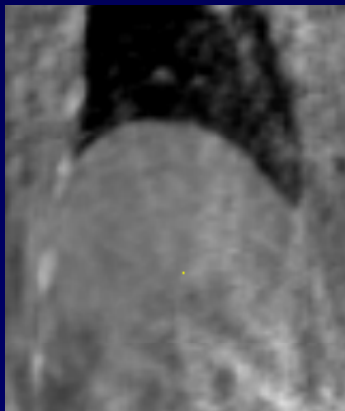
MR Integration, ...

4D (Temporal) IGRT

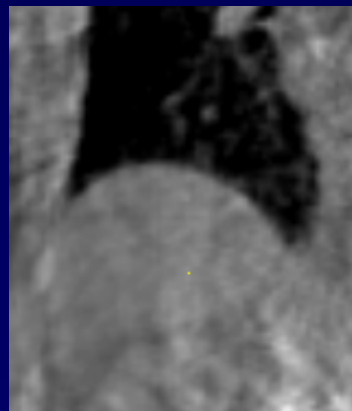
Respiratory Sorted kV
Cone Beam CT



CBCT

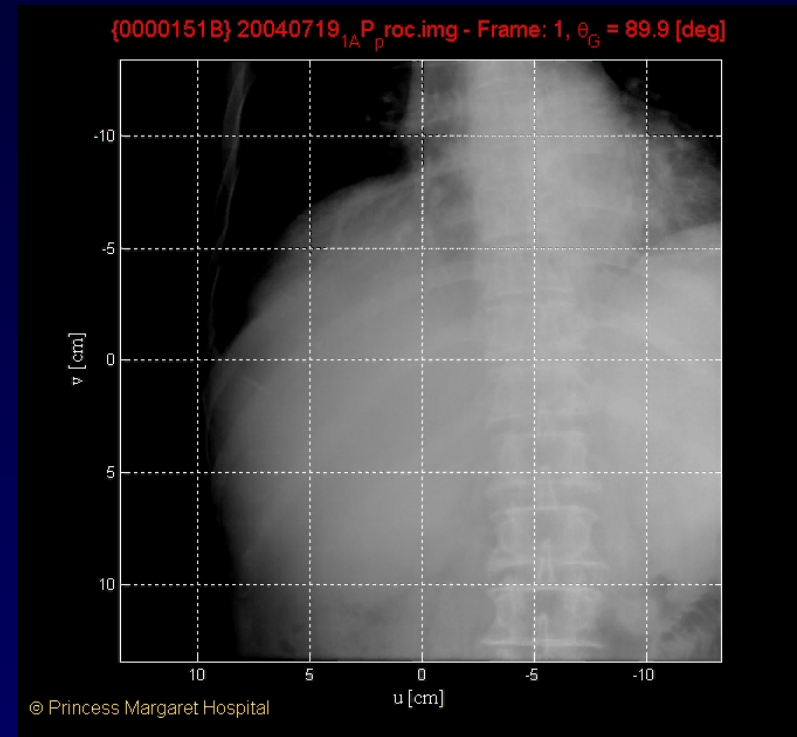


Exhale



Inhale

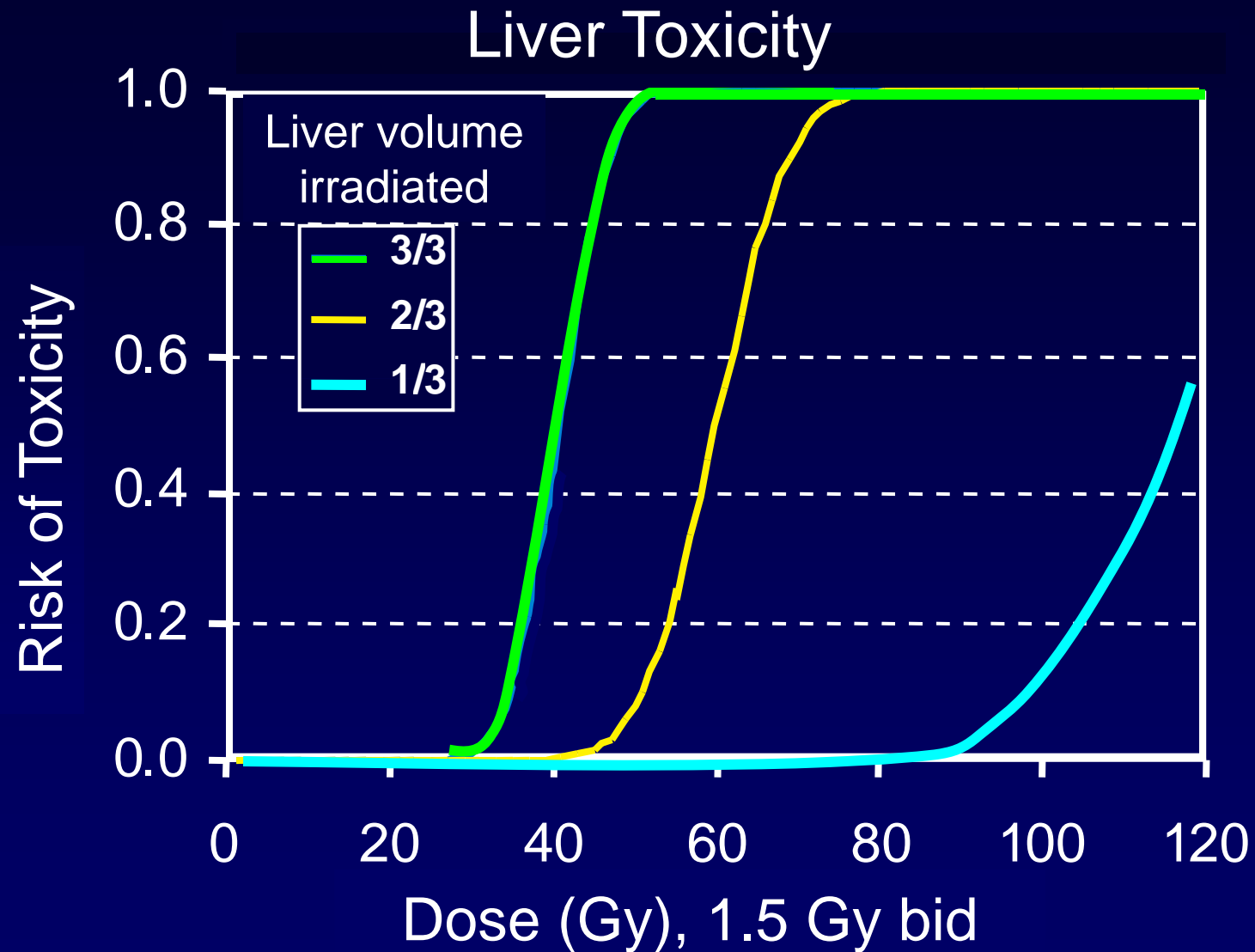
kV Fluoroscopy



- Improved accuracy
- Improved precision

Planned doses = delivered doses

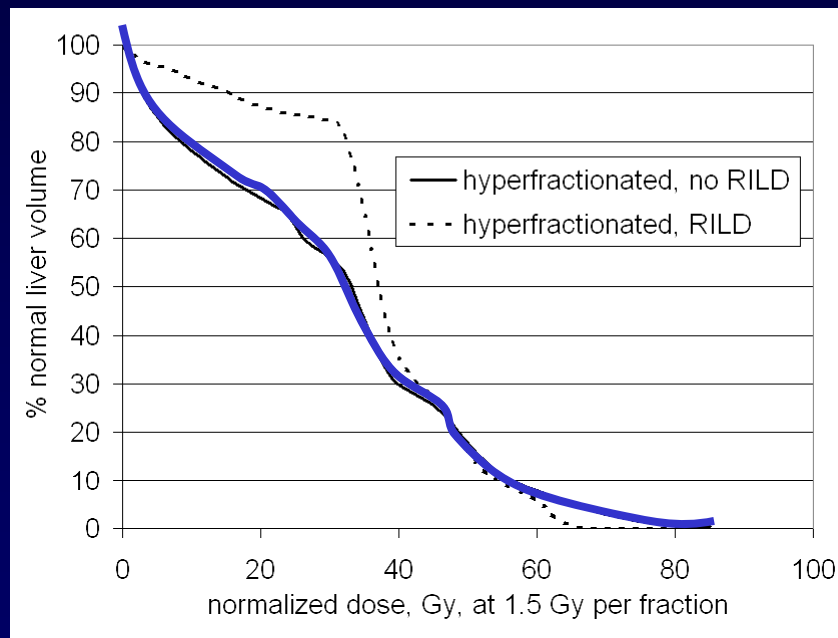
Understanding Normal Tissue RT Tolerances



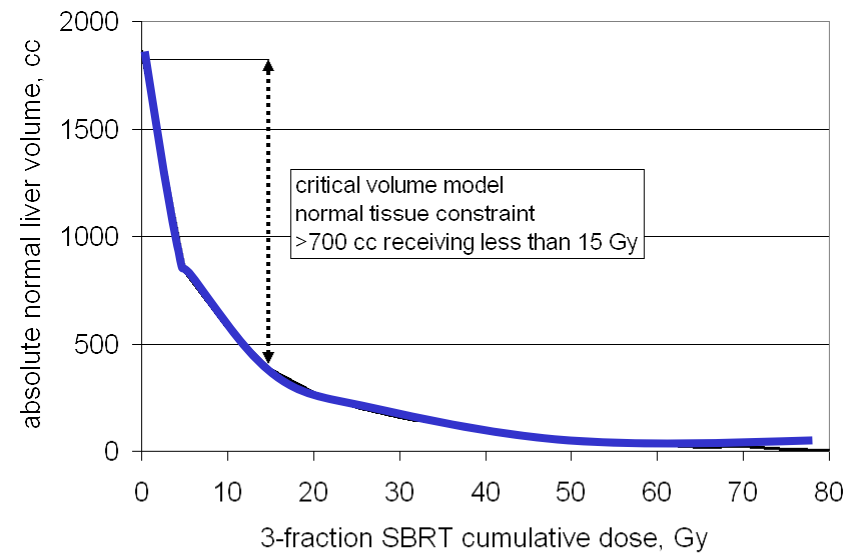
Understanding Normal Tissue RT Tolerances

- Collaboration and consensus

Michigan, hyper#

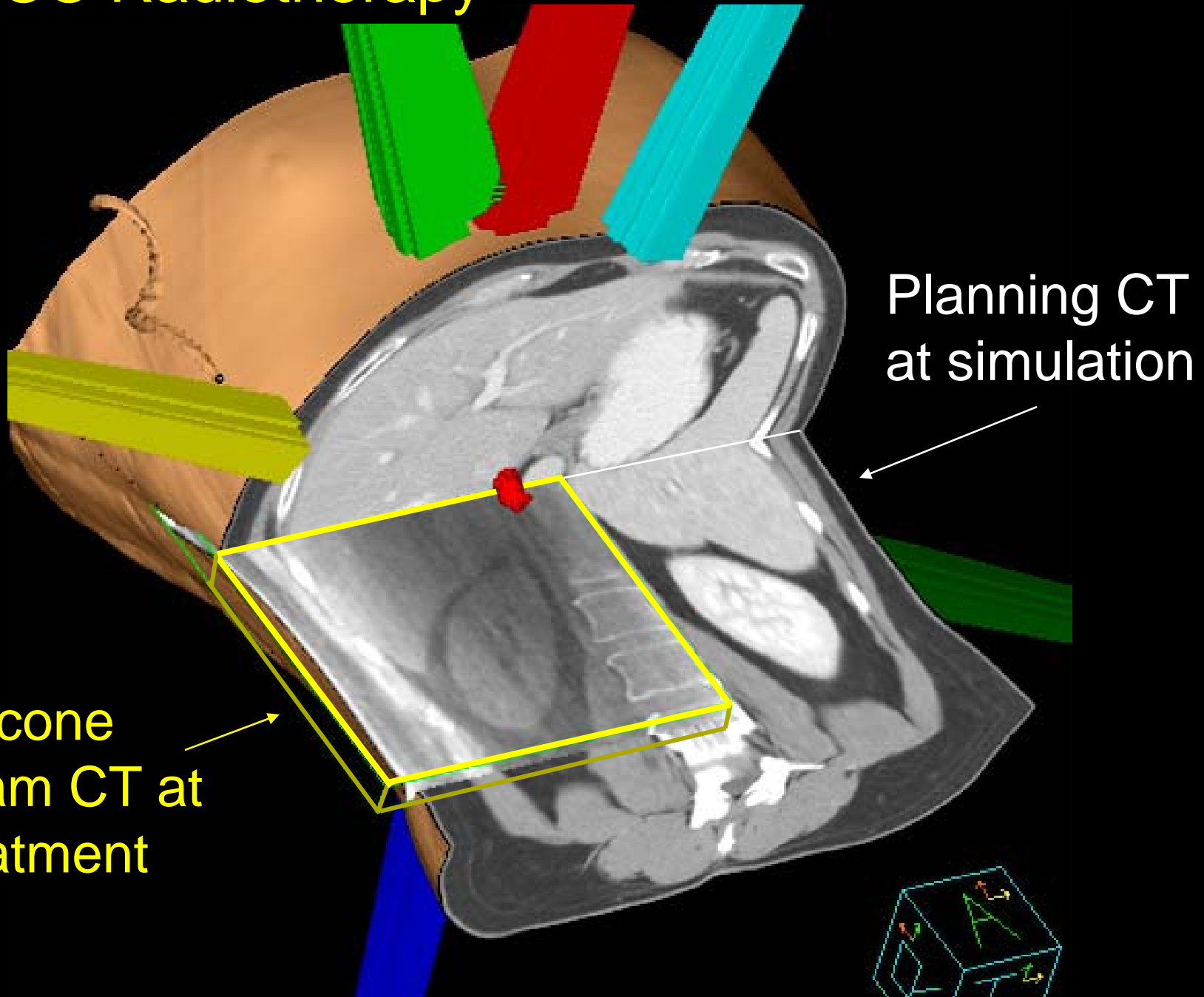


Colorado, 3 #



— Liver DVHs with no liver toxicity

HCC Radiotherapy



Planning CT
at simulation

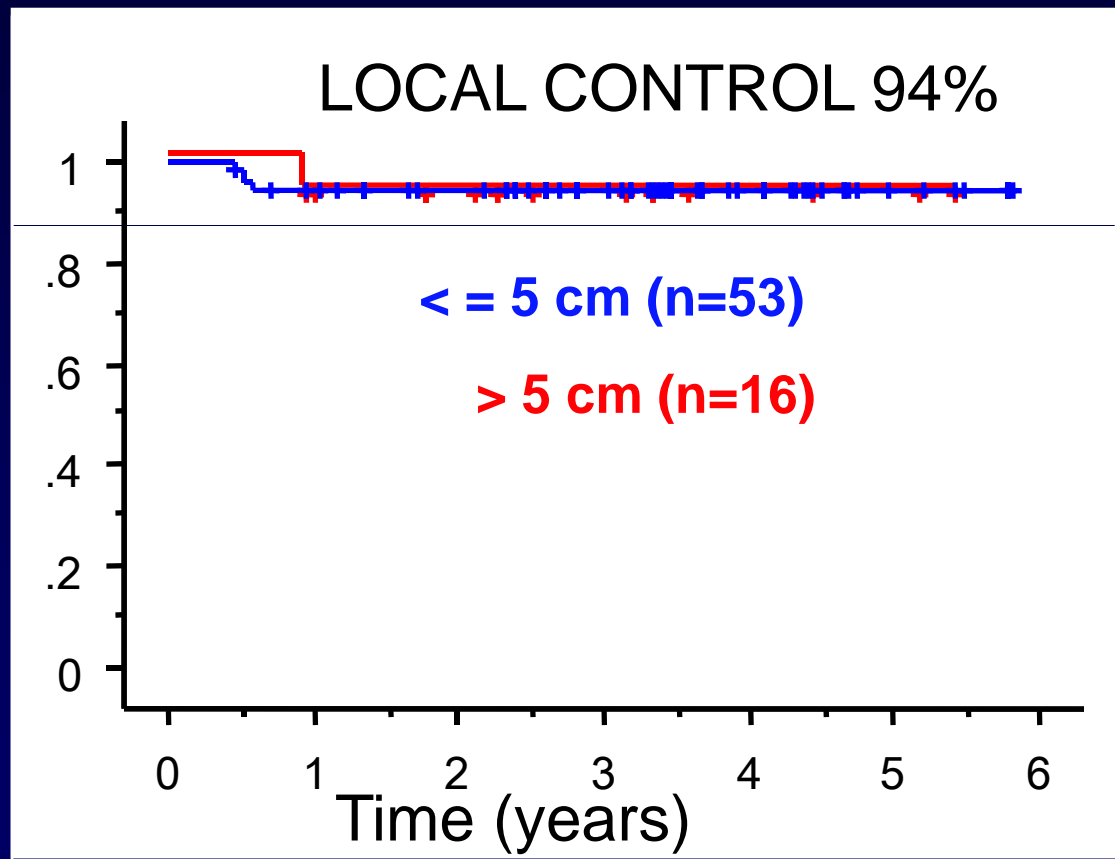
kV cone
beam CT at
treatment

Hepatocellular Carcinoma

- HCC - third cause of global cancer mortality
- Increasing in N America w increasing Hepatitis C
 - 18 000 cases / year US in 2006
- Local therapy can cure
 - Resection 50% 5 yr survival
 - Transplant 70% 5 year survival
- Predominantly hepatic recurrence
- < 15% of patients have resection/ transplant
- Overall 5 year survival < 10%

Carbon Ions for HCC: Japan n=69

- Phase II Study HCC: 52.8 Gy/ 4 # / 4 days
- Med follow-up of 5.4 years



Local control 94%

< 3 cm	100%
3-5 cm	90%
5-10 cm	93%
>10 cm	100%

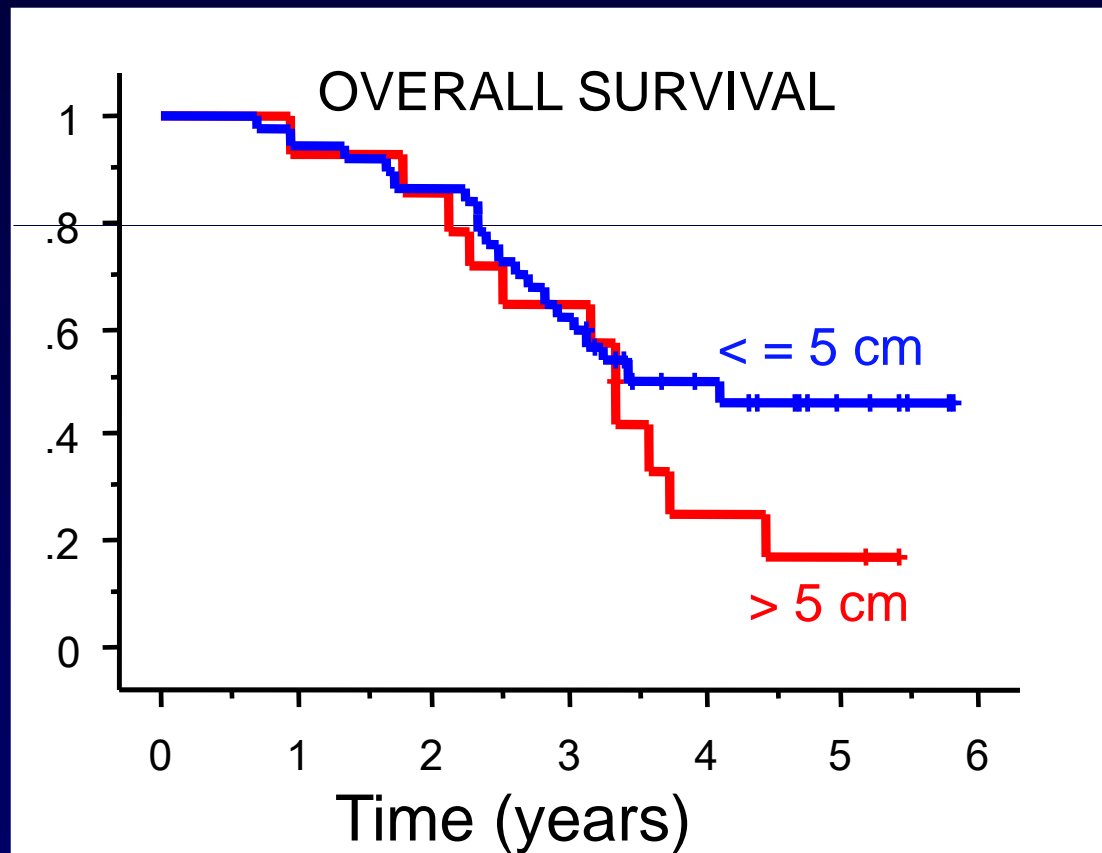
Gr. 3 toxicity n=3

Courtesy of H Tsujii, Japan

Kato H, Tsujii H, et al: ICLA 06 2007, Barcelona; Tsuji et al, New Journal of Physics 10, 2008

Carbon Ions for HCC: Japan n=69

- Phase II Study HCC: 52.8 Gy/ 4 # / 4 days
- Med follow-up of 5.4 years



Survival	3yr	5yr
< 5 cm	62%	36%
> 5 cm	64%	17%

Courtesy of H Tsujii, Japan

Kato H, Tsujii H, et al: ICLA 06 2007, Barcelona; Tsuji et al, New Journal of Physics 10, 2008

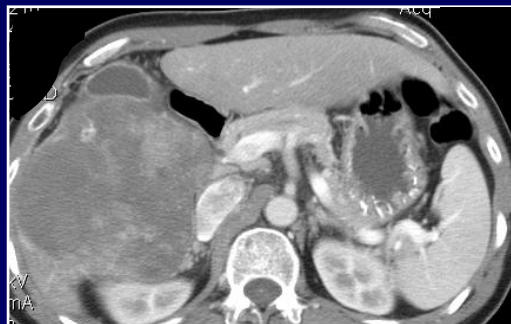PMH Phase I Study

- 41 patients
 - 31 HCC (52% portal vein thrombosis)
 - 10 intrahepatic cholangiocarcinoma (IHC)
- Median volume 172 cc (9 – 1913)
- Individualized therapy
 - Breath hold, IGRT, SBRT
- Median dose 36 Gy (24 – 54 Gy), 6 fractions
- No radiation induced liver disease (RILD)

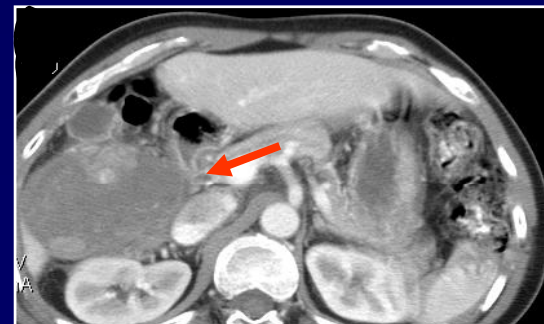Toxicity: PMH

- Grade 3 nausea/vomiting 1
- Grade 3 platelets 1
- Radiation Liver Disease, RILD 0
- Grade 3 liver enzymes 10 (8 preexisting)
- Decline in Child score 7 (5 with PD)
- 1 small bowel obstruction: 24 mo post RT
- 1 duodenal perforation: 15 mo post RT

Pre RT



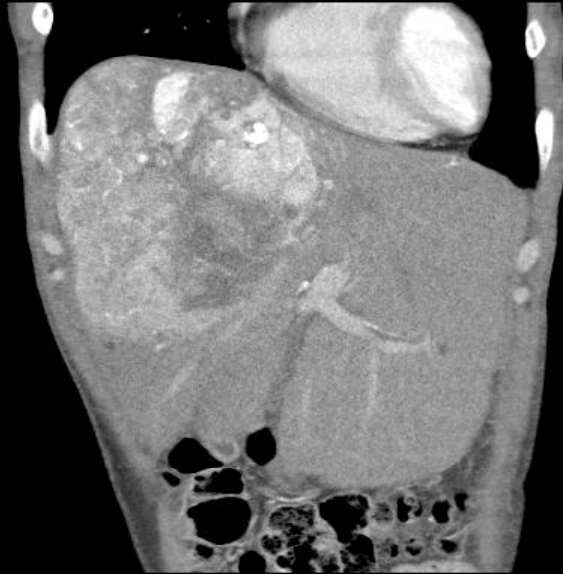15 mo post RT



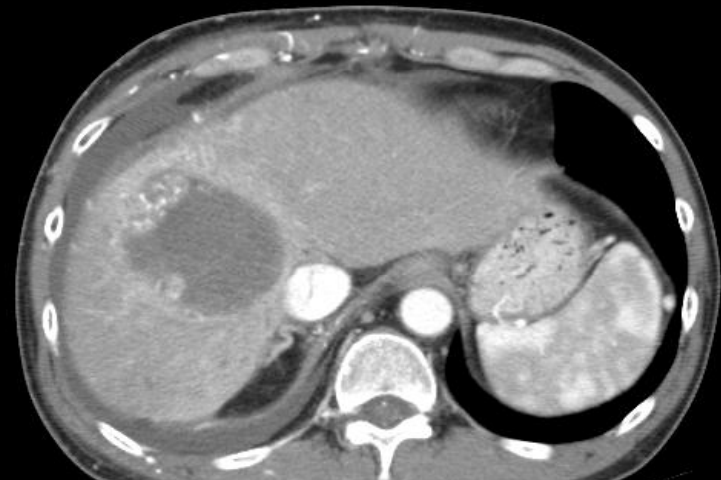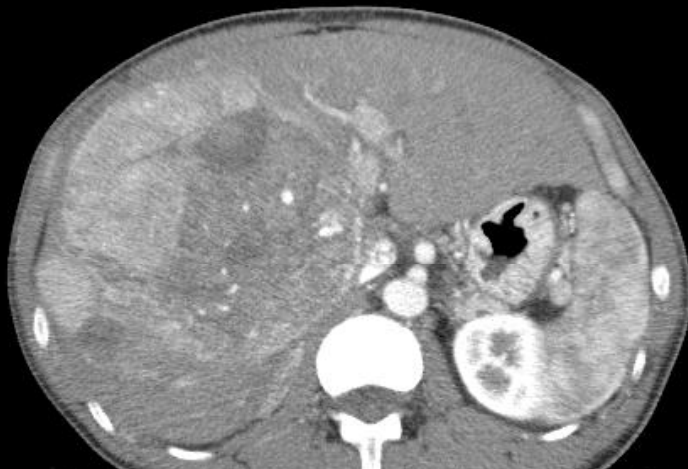
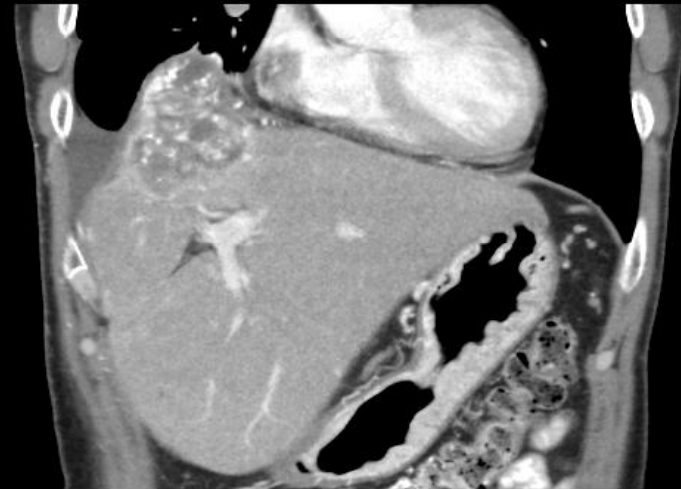Response: PMH

45 y.o. man – Hepatocellular carcinoma, 36 Gy/ 6 #

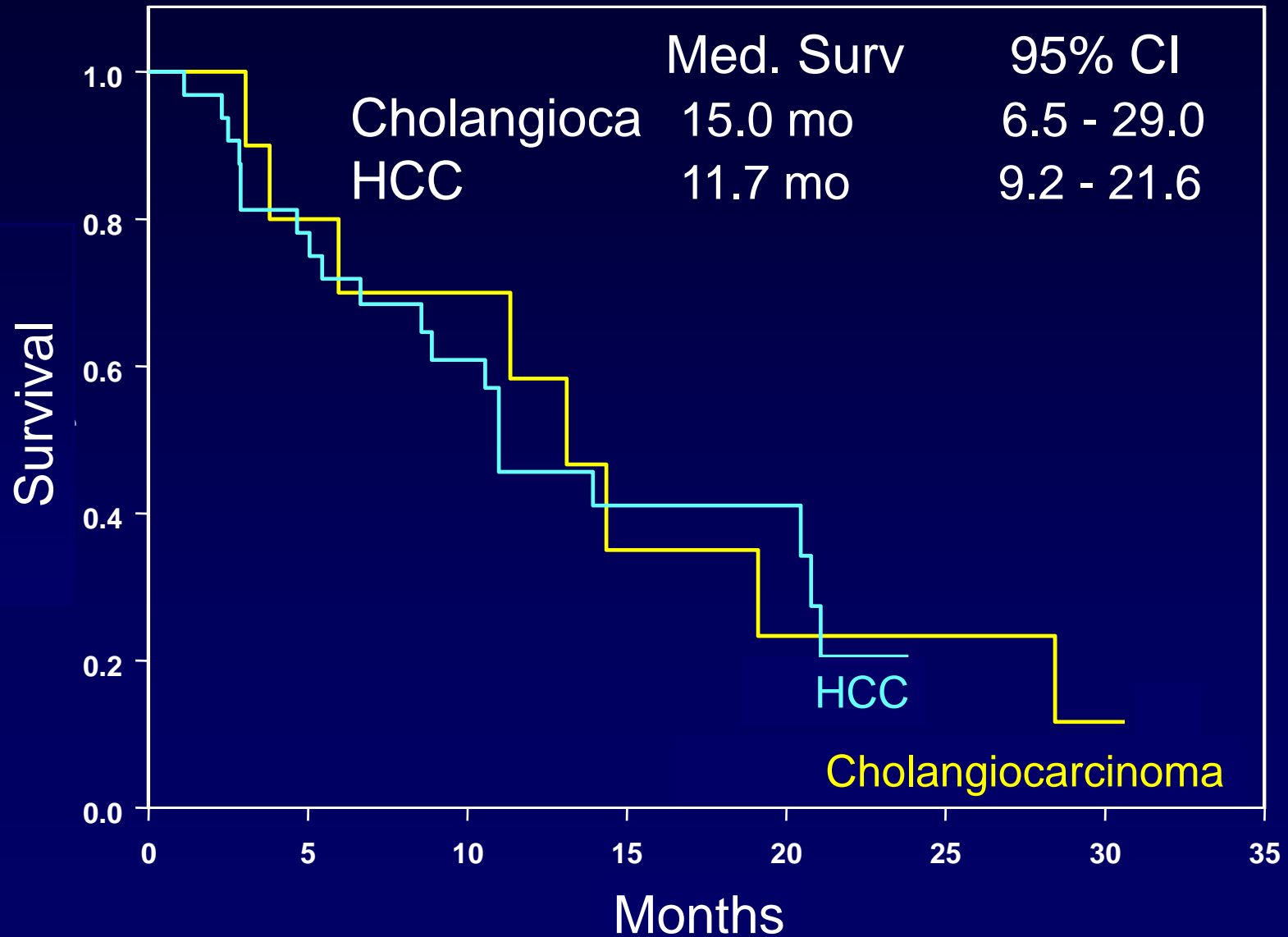
Baseline



9 months



Overall Survival: PMH



Future (Promising) Role of RT

- Biologic & image based improved patient selection
 - Micro-metastases identification
 - Treatment predictive biologic signatures
- Tumorcidal doses of RT to high risk targets only
 - Biologic highest risk tumor delineation
 - Individualized doses
 - Multiple strategies to control organ motion
- Avoidance of normal tissue toxicity
- Improved integration of RT with other therapies
- Improved outcomes for upper abdominal cancers

Acknowledgements

PMH GI site group, HCC tumor board, referring physicians and patients

Image Guidance

David Jaffray

Doug Moseley

Mike Sharpe

Kristy Brock

Tom Purdie

Patricia Lindsay

NKI / AvL Amsterdam

Jan Jakob Sonke

Marcel van Herk

ASCO CDA (Dawson)

NCIC

Canadian Cancer Society

Elekta

High Precision Liver RT

Mark Lee

Maria Hawkins

Regina Tse

Robert Case

Cynthia Eccles

Tim Craig

John Kim

Rob Dinniwell

Jim Brierley

Jolie Ringash

Rebecca Ringash

Bernard Cummings

Jean-Pierre Bissonnette

Kristy Brock

Gina Lockwood

Andrea Marshall