

Colorectal Cancer PET-CT vs CT


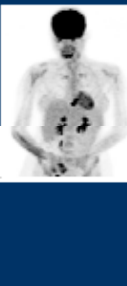
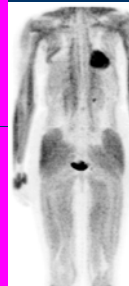
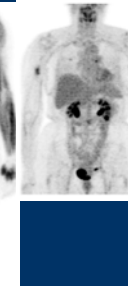
2009


Tim Akhurst MD FRACP
Associate Attending MSKCC
New York New York

What does FDG add to CT?

- Function rather than anatomy or perfusion
- Biologic contrast agent adds value to anatomic and perfusion data (iodinated contrast)

FDG PET is Biology, NOT Anatomy

Patient A Osteosarcoma		Patient B Synovial sarcoma	
			
8/12/2002	8/16/2002	9/23/1997 BSL=89	9/25/1997 BSL=77

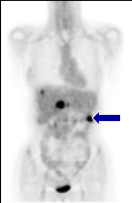



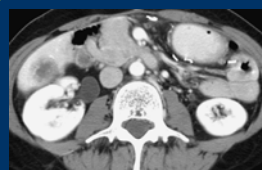


ue

How many lesions can you detect on a single slice

Tim Akhurst 2009

Anatomic vs Functional Imaging.

Range of acquisition

PET is whole body screen :- mid skull to proximal thighs

CT is part specific

- Neck
- Chest
- Abdomen
- Pelvis

Tim Akhurst 2009

Dedicated versus screening acquisition

3 minutes
2D
Jan 17 2008
(GE DLS)

10 minutes
3D
Jan 8 2008
(GE DLS)

Dedicated versus Screening acquisition

3 minutes
2D
Jan 17 2008
(GE DLS)

10 minutes
3D
Jan 8 2008
(GE DLS)

What does CT of a PET-CT add to FDG PET alone

- Faster Attenuation scan
- More accurate co-localization

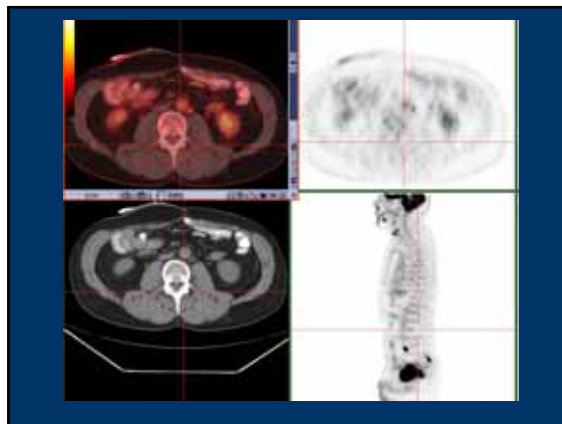
Tim Ahurst 2009

Rectal Cancer Nodes

PET/CT

PET/CT

Sometimes the Correlations can be Exquisite



Dosimetry

Germanium rod sources gave trivial increases in dose compared to the FDG dose
 CT may give more dose than the FDG depending on the way the CT is done

Table 4. Effective doses in a one-session PET examination with routine imaging parameters (mean±SD)

External transmission	Effective dose (mSv)		
	Brain	Cardiac	Whole body
Germanium-based			
ECAT EXACT HR*	0.02±0.001 (10 min)	0.08±0.004 (10 min)	0.20±0.002 (35 min)
Advance NX†	0.03±0.001 (10 min)	0.13±0.003 (10 min)	0.26±0.017 (35 min)
CT-based			
CTM _{APRISON}	0.45±0.02 (9 s)	5.66±0.19 (9 s)	18.97±0.46 (58 s)
CTM _{ILUMIN}	0.22±0.01 (5 s)	3.25±0.32 (5 s)	8.81±0.23 (26 s)
CTM _{ALISON}	0.02±0.01 (5 s)	0.23±0.01 (5 s)	0.72±0.08 (26 s)
Internal emission, MIRD*	10.73±3.48		

Note: The values in the parenthesis are the scanning times for brain, cardiac (both contain one axial FOV) and whole-body (spans seven axial FOVs) transmission measurements, respectively. *MIRD of 10.73±3.48 for 370 MBq of total administered activity with ¹⁸F-FDG (Deleau et al.)

Wu et al. Eur J Nucl Med Mol Imaging 31:38-43, 2004.

In general no study should be ordered unless it is likely to provide data that will aid clinical management.

We are imaging patients with cancer.

There is NO ROLE for “social” screening

Tim Ashurst 2009

Japanese Screen of 59 year olds
 n=2911

- 0.96 % prevalence of detectable cancer in patients undergoing a screening FDG PET CT scan. Sensitivity 18%
Ann Nucl Med. 2008 Jun;22(5):379-85.

PET Registry Study: n = 22,976

- Management change in cancer patients >36%
Journal of Clinical Oncology, Vol 26, No 13 (May 1), 2008: pp. 2155-2161

All that Glitters.....

Pouchitis

The image displays three PET/CT scans. The leftmost scan is a sagittal view showing a bright, localized area of increased FDG uptake in the sigmoid colon. The middle scan is an axial view showing a similar area of uptake. The rightmost scan is a coronal view showing the uptake in the sigmoid colon. The word 'Pouchitis' is written in large white letters over the scans.

Mucinous versus non-Mucinous

- ◆ Sensitivity for mucinous less than for non-mucinous Colon ca
 - 58% (n=16) versus 92% (n=93)
- ◆ Dis Colon Rectum. 2000 Jun;43(6):759-67
 - Usefulness of FDG-PET scan in the assessment of **suspected metastatic or recurrent** adenocarcinoma of the colon and rectum.

Whiteford MH et al

The image shows the cover of the journal 'Diseases of the Colon & Rectum'. The cover is blue with white text and a small image of a colon.

Metformin Therapy: Normal Colonic Uptake

The image shows three PET scans. The leftmost scan is a coronal view showing normal colonic uptake. The middle scan is an axial view showing normal colonic uptake. The rightmost scan is a coronal view showing normal colonic uptake.

High and typical (18)F-FDG bowel uptake in patients treated with metformin.
 Gontier E, Fourme E, Wartski M, Blondet C, Bonardel G, Le Stanc E, Mantzarides M, Fochrenbach H, Pecking AP, Alberini JL. : Eur J Nucl Med Mol Imaging. 2008 Jan;35(1):95-9.

FDG PET Imaging of Colorectal Cancer

- Diagnosis
 - ◆ Initial Staging
 - ◆ Evaluation of induction therapy for rectal cancer
 - ◆ Evaluation of patients with potentially resectable metastases
 - ◆ Evaluation of equivocal tests CT / CEA etc
 - ◆ Post therapy evaluation PROGNOSIS

Rectal Cancer Staging

	ROUTINE	SELECTIVE
◆ Lesion Detection	Colonoscopy	Ba Enema Virtual Colon
◆ T, N Stage	Clinical Exam Endorectal U/S Dedicated CT	MRI CT-PET
◆ M Stage	Spiral CT	MR, U/S
◆ Tumor Biology	Biopsy Morphology	FDG PET

Comparative studies with FDG and CT alone

Most studies were conducted to provide a rationale for reimbursement of FDG PET imaging.

Early studies used "old" CT technology.

Tim Alhazni 2009

Initial Staging of Rectal Cancer

- 83 patients
 - Prior imaging.
 - Abdominopelvic CT n=83
 - CT Chest or CXR n=76
 - Pelvic MRI n=54
 - Endoanal U/S n=23 >both n=6 =total of 83

Dis Colon Rectum 2008; 51: 997-1003

Conventional versus PET-CT stage

CI stage group	PET-CT stage group						
	1	2A	2B	3A	3B	3C	4
1	6	0	0	0	0	0	0
2A	0	18	0	0	3	0	3
2B	0	0	2	0	1	0	0
3A	1	0	0	0	0	0	1
3B	0	6	0	0	16	3	1
3C	0	0	0	1	2	1	0
4	1	1	0	0	2	0	14

Impact of PET on staging 26/83=31%

	Change CI –PET-CT	Count	Percent
Downstaged (n = 14)	N1 – N0	7	50
	N2 – N1	3	21
	M1 – M0	3	21
	N1M1 – N0M0	1	7
Upstaged (n = 12)	N0 – N1	4	33
	N1 – N2	3	25
	M0 – M1	2	16
	MX – M1	2	17
	NOMX – N1M1	1	8

Was PET correct?

- Upstaged 4/12 widespread mets, confirmed on imaging
7/12 nodal mets identified 4 mesorectal (resected), 3 iliac nodes (Rx chemo- became negative on imaging), 1/12 both nodal and systemic mets
- Downstaged 3/14 no mets on PET, confirmed on F/Up
- 7/14 mesorectal nodes called negative (resected), 3/14 iliac nodes negative (resected; 2 post ChemoRT)

Did it matter?

- Management was changed in 14%
- Dis Colon Rectum 2008; 51: 997-1003

Compared to

- Management was changed in 27%
- Ann Surg Oncol 2006; 13: 397-404
 - Why, more low rectal cancers
 - More inguinal nodes:- change RT plan

Colorectal Cancer: Radiation therapy.

- Responds to chemoradiation induction therapy
- This change can be monitored with FDG PET

FDG PET Imaging of Colorectal Cancer

- Diagnosis
- ◆ Initial Staging
- ◆ Evaluation of induction therapy for rectal cancer
- ◆ Evaluation of patients with potentially resectable metastases
- ◆ Evaluation of equivocal tests CT / CEA etc
- ◆ Post therapy evaluation PROGNOSIS

Rectal Cancer Response post FOLFOX

05/07/2008 21

06/25/2008 7.5

Rectal Cancer Nodal Disease

05/07/2008

06/25/2008

RECTAL CANCER RESPONSE ASSESSMENT

Baseline 11/12/01

Intermediate 12/11/01

Late 1/24/02

Rectal Cancer : RT/Chemo

5/8/97

8/8/97

2/11/2000

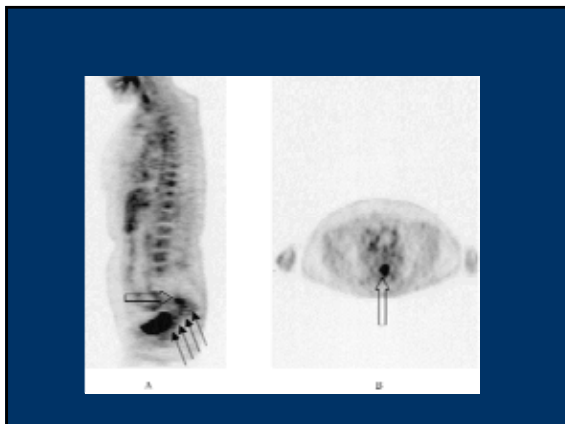
5/24/2000

JACS 199 1 July 2004 PP 1-7

Journal of the American College of Surgeons

Sequential preoperative fluorodeoxyglucose-positron emission tomography assessment of response to preoperative chemoradiation: a means for determining long-term outcomes of rectal cancer

DOI: 10.1016/j.jamcollsurg.2004.02.024



FDG PET Imaging of Colorectal Cancer

- Diagnosis
- Initial Staging
- Evaluation of induction therapy for rectal cancer
- Evaluation of patients with potentially resectable metastases
- Evaluation of equivocal tests CT / CEA etc
- Post therapy evaluation PROGNOSIS

Curative surgery of Metastases

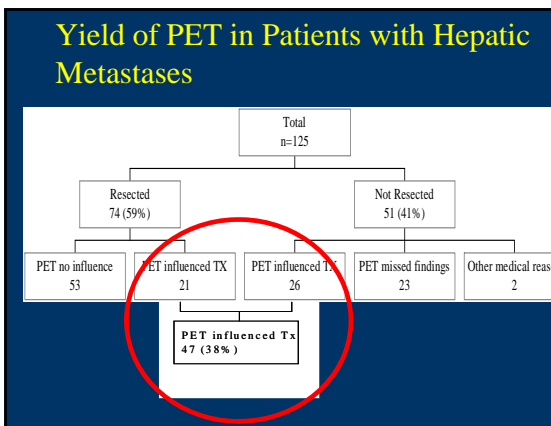
Preoperative Prediction of Prognosis Post Liver Resection n=1001

- Fong et al Ann Surg 1999 230 (3): 309
 - Clinical risk score
 - » Node positive primary
 - » Disease free <12 months
 - » > 1 tumor
 - » Size > 5cm
 - » CEA >200ng/ml

Score	5 yr survival %	Median Survival (months)
0	60	74
1	44	51
2	40	47
3	20	33
4	25	20
5	14	22

This has been revalidated

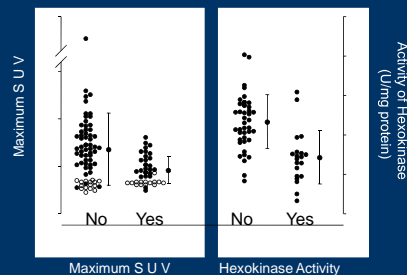
- ### Study Design
- #### PET and Hepatic Metastases
- ♦ Diagnosis of colorectal carcinoma
 - ♦ Candidates for liver resection (n=125)
 - ♦ No history of diabetes
 - ♦ Complete history and physical examination
 - ♦ Helical CT scan of the chest, abdomen, and pelvis
 - ♦ CT portography
 - ♦ ¹⁸F-FDG / PET scan
 - ♦ Chemotherapy was NOT an exclusion criterion



Yield of 18F-FDG PET In The Liver

	PET+	PET-	Total	%
<1 cm	2	22	24	8
1-2 cm	28	7	35	80
2-3 cm	17	1	18	94
>3 cm	32	1	33	97
Total	79	31	110	72

Yield of PET Related to Prior Chemotherapy

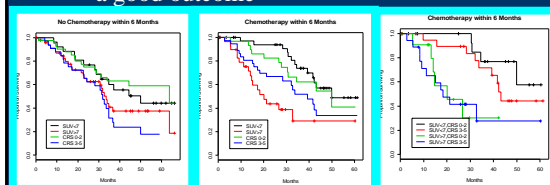


FDG PET Imaging of Colorectal Cancer

- Diagnosis
- Initial Staging
- Evaluation of induction therapy for rectal cancer
- Evaluation of patients with potentially resectable metastases
- Evaluation of equivocal tests CT / CEA etc
- Post therapy evaluation **PROGNOSIS**

Response Assessment Re-staging Liver metastases

- A negative PET scan is a good predictor of a good outcome



FDG PET Adds to CRS

- No chemotherapy within 6/12 rely on CRS
 - » SUV not very helpful in determining prognosis
- If chemotherapy within 6/12 forget the CRS use SUV instead.
 - » Cox proportional hazard 1.44 p=0.0027

Does the Novel PET/CT Imaging Modality Impact on the Treatment of Patients With Metastatic Colorectal Cancer of the Liver?



Seizner, Markus MD

Volume 240(6) December 2004 pp 1027-1036

- Conventional CT greater sensitivity than PET-CT in the liver
- Nodal disease detected better with PET-CT
- Extra-hepatic disease detected better with PET-CT
- Local Recurrence detected better with PET-CT
- Hepatic recurrence detected better with PET-CT

Does the Novel PET/CT Imaging Modality Impact on the Treatment of Patients With Metastatic Colorectal Cancer of the Liver?

- ◆ No ROC analysis
- ◆ Patient treatment changed 21% of the time.

FDG PET PYSIOLOGY

- ◆ Mandates good communication between a clinician and a reader
- ◆ The clinical context in which a scan is done will change the outcome of the scan dramatically
- ◆ The information within the scan is different according to the clinical context.

In summary: FDG PET

- ◆ FDG PET can be thought of as real time tumor imaging
- ◆ At diagnosis 14-30% patients management will be changed by PET post Conventional Imaging
- ◆ FDG uptake in untreated tumors is prognostically important and appears to be associated with other more traditional markers of aggressive disease.
- ◆ Changes in FDG PET uptake during the course of therapy appear to be prognostically important

FDG PET Imaging of Colorectal Cancer

- Diagnosis
- ◆ Initial Staging
- ◆ Evaluation of induction therapy for rectal cancer
- ◆ Evaluation of patients with potentially resectable metastases
- ◆ Evaluation of equivocal tests CT / CEA etc
- ◆ Post therapy evaluation PROGNOSIS
- ◆ *Any new drug introduced into the clinic should be introduced with a robust method of early response assessment*
- ◆ *Patients on clinical trials should undergo FDG PET scanning to evaluate the efficacy of FDG PET in assessing response*